

Ocular Coherence Tomography Supports an Investigational New Drug Application for a C3 Complement Inhibitor Targeting Macular Degeneration

Margaret Collins¹, Jason Slakter², Robert J. Munger³, Patty Wells¹, Collin Kolodziej¹, Pascal Deschatelets⁴, Federico Grossi⁴, Ray Stoll⁵

¹ Charles River, Reno, NV, United States; ² NYU Medical School, Great Neck, NY, United States; ³ Animal Ophthalmology Clinic, Dallas, TX, United States;

⁴ Apellis Pharmaceuticals, Crestwood, KY, United States; ⁵ Stoll and Associates, Storrs Mansfield, CT, United States

Abstract

APL-2, a peptide conjugate that inhibits complement C3, was assessed for 9 months following monthly intravitreal (IVT) injection (50 or 100 μ L) to cynomolgus monkeys at dose levels of 3.1, 12.4, and 24.8 mg/eye. Vehicle (5% Dextrose, USP) and control article (unfunctionalized conjugate backbone) groups were included. The results presented cover an interim phase which included 3 doses. Clinical signs, body weights, ophthalmology, electroretinography (ERG), tonometry, spectral domain optical coherence tomography (SD-OCT), clinical pathology, and bioanalysis parameters (serum bioanalysis, anti-drug antibody (ADA), CH50) were evaluated. No interim necropsy occurred.

Procedure-related ocular findings included clinical signs of eye opacity and pupil dilation, ophthalmic findings of aqueous flare and cells, and vitreous haze, and decreased intraocular pressure. All findings were in one eye of a single 24.8 mg/eye/dose animal, except for pupil dilation (also noted in one vehicle-treated animal). Cells were noted in the anterior vitreous of control article and APL-2 animals.

Increases in serum exposure for the 12.4 mg/eye group were slightly less than dose proportional relative to the 3.1 mg/eye group, but were generally dose proportional in the 24.8 mg/eye group relative to the 12.4 mg/eye group. No sex differences or antigenicity were detected for APL-2 or the conjugate backbone.

SD-OCT evaluation was used as the primary means of assessing the retina at the interim time point and demonstrated no test article-related retinal changes. The use of OCT was a pivotal component of an Investigational New Drug (IND) application that was opened in the US in November, 2014. On the basis of these findings, the Phase I clinical trials were initiated.

Materials & Methods

Group No.	Test Material	Dose Level (mg/eye/dose)	Dose Volume (μ L/eye)	Dose Concentration (mg/ μ L)	No. of Animals	
					Males	Females
1	Vehicle	0	50	0	3	3
2	Control Article	0	100	0	3	3
3	APL-2	3.1	50	0.062	3	3
4	APL-2	12.4	50	0.248	3	3
5	APL-2	24.8	100	0.248	3	3

Chinese cynomolgus monkeys were used for this study. Intravitreal injections were delivered to both eyes every 4 weeks. For animals that received a 100 μ L injection, 50 μ L of vitreous humor was aspirated prior to injection. The following parameters and end points were evaluated during the study: clinical signs and food consumption, body weights, ophthalmology (slit lamp biomicroscopy and indirect ophthalmoscopy), electroretinography (ERG), tonometry, optical coherence tomography, clinical pathology parameters (hematology, coagulation, and clinical chemistry), bioanalysis, ADA analysis, and CH50 analysis. No interim necropsy was conducted. The results presented cover an interim phase which included the first 3 doses.

Results

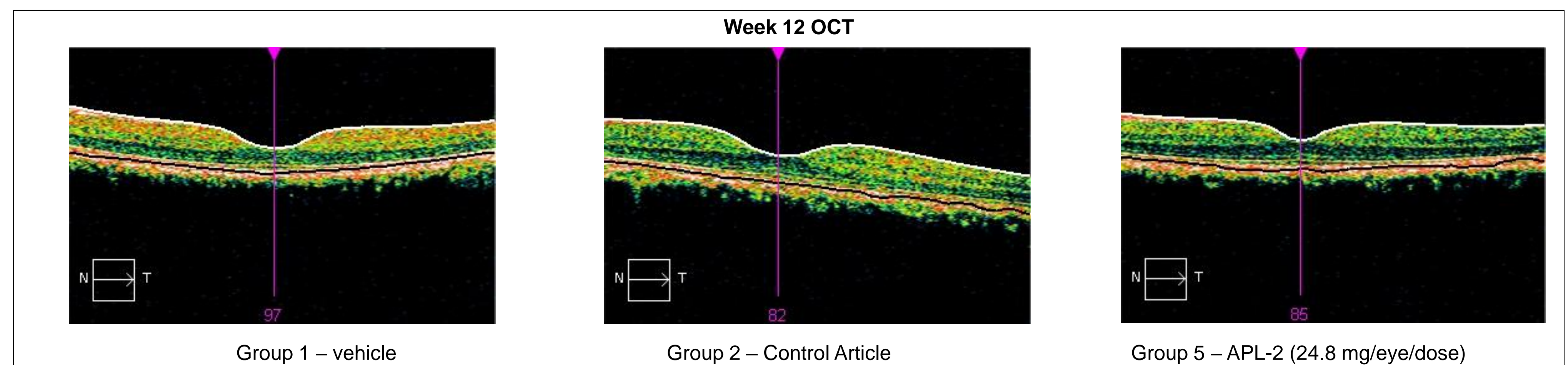
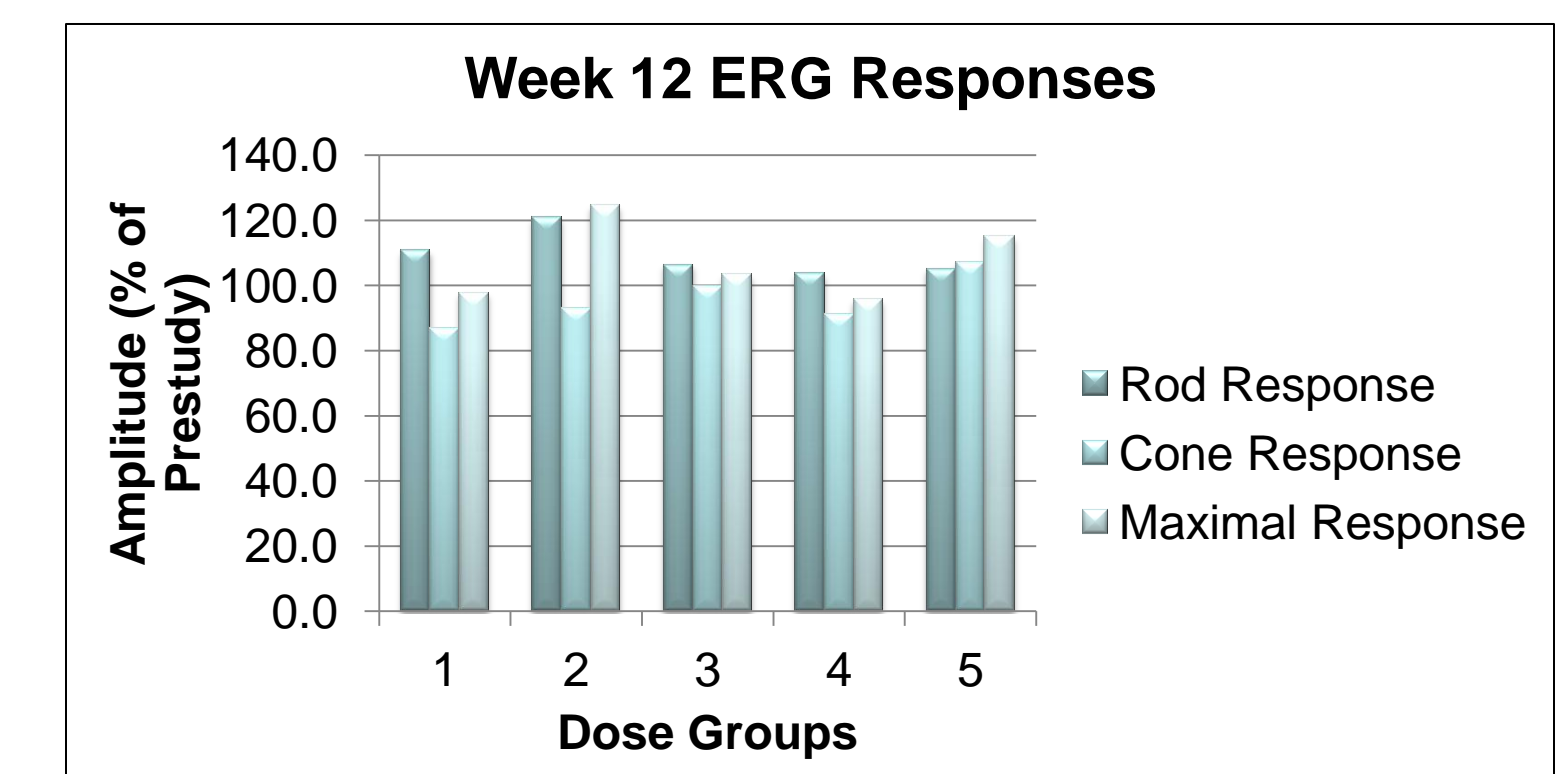
Ocular clinical signs, ophthalmologic findings and tonometry findings were limited to inflammation and associated changes in intraocular pressure (IOP) that were noted in vehicle-, control article-, and/or test article-treated animals and were not noted in both eyes of any animal. Procedure-related ocular findings included clinical signs of eye opacity and pupil dilation, ophthalmic findings of aqueous flare and cells, and vitreous haze, and decreased intraocular pressure. Cells were noted in the anterior vitreous of control article and APL-2 animals. As such, these ocular findings were considered procedure-related or control article-related.

OCT evaluation demonstrated no test article-related retinal changes. Decreases in macular volume of ≥ 1.5 but ≤ 3 and > 3 mm^3 were observed in one Group 2 female animal and one Group 5 female animal, respectively. A decrease in central retinal thickness of ≥ 20 but ≤ 40 μm was observed in one Group 1 female animal. Increases in central retinal thickness of ≥ 20 but ≤ 40 μm occurred in 2 females and 1 male in Group 1, 1 male in Group 2 and the right eye of 1 male in Group 4. The Group 4 male also had an increase in central retinal thickness of > 40 μm in the left eye. The extent and frequency of these changes are considered incidental and unrelated to the administration of APL-2.

There were no test article-related changes noted for body weights, clinical pathology parameters, or CH50 levels.

Results

Serum exposure levels were generally similar for males and females in each group. Increases in the 12.4 mg/eye dose group were slightly less than dose proportional relative to the 3.1 mg/eye dose group. Increases in the 24.8 mg/eye dose group were generally dose proportional relative to the 12.4 mg/eye dose group. Concentrations generally peaked 144 hours (6 days) following each injection. There was slight accumulation between the first and second doses, but peak concentrations were comparable between the second and third doses. No antigenicity was detected for APL-2 or the conjugate backbone.



Conclusions

SD-OCT evaluation was used as the primary means of assessing the retina at the interim time point and demonstrated no test article-related retinal changes. The use of OCT was a pivotal component of an IND that was opened in November, 2014. On the basis of these findings, the Phase I clinical trials were initiated.